

Aetiology of neovascular glaucoma among patients attending a tertiary eye care centre in South India

Dr Hari Ramakrishnan DO DNB FRCS(Glasg), Dr Suseela B Nair DO MS

Abstract: Neovascular glaucoma (NVG) is a highly intractable form of secondary glaucoma caused by the development of a fibrovascular tissue in the angle of the eye. Retinal hypoxia caused by a number of diseases is responsible for this condition. This study was undertaken to assess the various etiological factors for neovascular glaucoma. Among the 42 eyes studied the commonest cause encountered was Proliferative Diabetic Retinopathy (PDR -19 eyes). Central Retinal Vein Occlusion was seen in 15 eyes. Other causes noted were retinal vasculitis (2 eyes), central retinal artery occlusion (1 eye), carotid artery disease (1 eye) combined arterial and venous occlusion (1 eye), Coat's disease (1 eye), chronic uveitis (1eye) and undetermined (1 eye).

Index Terms : Glaucoma, retinal hypoxia, neovascular, aetiology, CRVO, proliferative diabetic retinopathy

Introduction

Neovascular glaucoma (NVG) is a highly intractable form of secondary glaucoma caused by the development of a fibrovascular tissue in the angle of the eye. In the early stages it is an open angle glaucoma caused by obstruction to aqueous drainage and in late stages, angle closure glaucoma caused by contraction of the fibrovascular membrane resulting in synechial angle closure. Retinal hypoxia has been found to be the basic cause for this condition. Hypoxic areas of the retina produce angiogenic factors which are responsible for the development of new vessels. Vascular Endothelial Growth Factor (VEGF) is the most important angiogenic factor and has been isolated from the eyes of patients with neovascular glaucoma^{1,2}.

Neovascular glaucoma can occur following a variety of ocular diseases associated with retinal hypoxia, but proliferative diabetic retinopathy (PDR) and central retinal vein occlusion (CRVO) are the commonest causes implicated³. The present study was undertaken to assess the various etiological factors of neovascular glaucoma among patients attending our hospital.

Aim:

To analyze the common causes of neovascular glaucoma

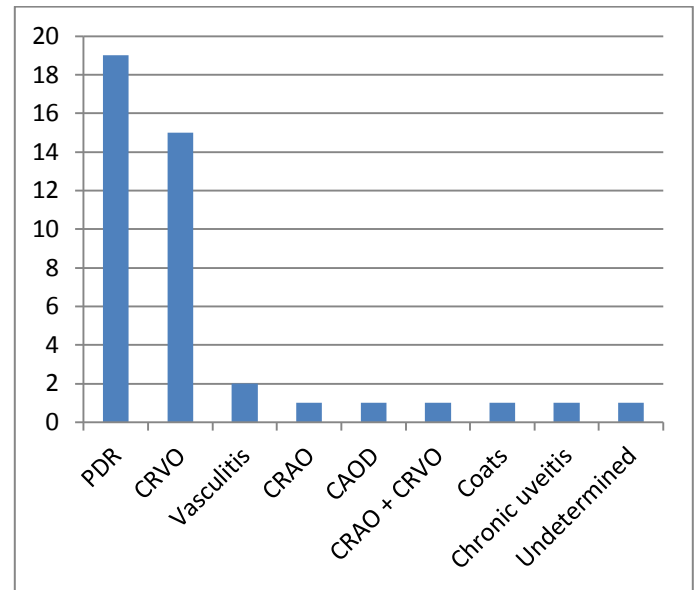
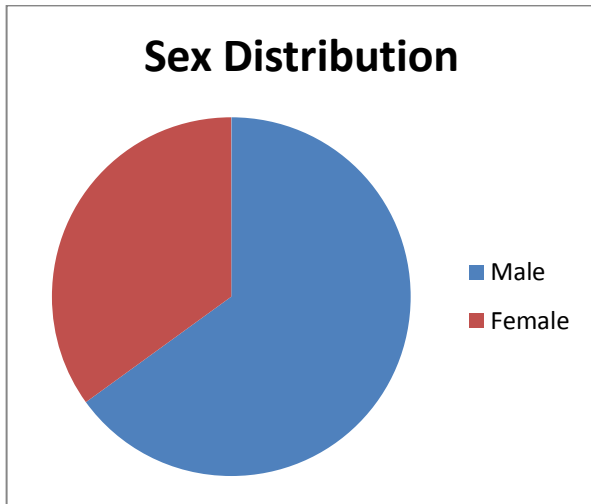
Methods:

This was a prospective study of 42 eyes of 40 patients conducted at Chaithanya Eye Hospital and Research Institute. Patients with neovascular glaucoma who attended the outpatient department from March 2004 to June 2005 were included in the study.

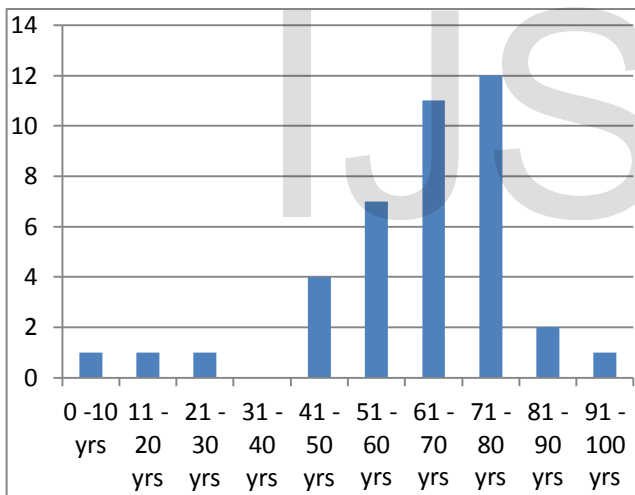
A detailed history was taken, with particular reference to diabetes mellitus, systemic hypertension, cardiovascular disease and ocular diseases like glaucoma. Both eyes were examined in detail including refraction, slit lamp biomicroscopy, fundus examination, intra ocular pressure and gonioscopy. B Scan ultrasonography and visual field charting were performed in relevant cases. Systemic examination was also carried out. Investigations like blood sugar levels, serum cholesterol, glycosylated Hb, urinalysis and renal function tests were done when required.

Observation and Results:

There were 42 eyes totally. Two patients had bilateral disease. Out of the 40 patients who were included in the study, 26 were male and 14 were female. The majority of patients belonged to the age group of 40 to 80 years.



Distribution of Age



The commonest cause of NVG encountered in our study was PDR (19 eyes). CRVO was seen in 15 eyes. Other causes noted were retinal vasculitis (2 eyes), central retinal artery occlusion (1 eye), carotid artery disease (1 eye) combined arterial and venous occlusion (1 eye), Coat's disease (1 eye), chronic uveitis (1eye) and undetermined (1 eye). This is similar to studies conducted by Brown et al who reported that Diabetic retinopathy and CRVO were the most common causes of NVG in their series³. Later studies have also shown a similar trend⁴.

Discussion and Conclusion

Neovascular glaucoma is a relatively common potentially devastating eye disease caused by the proliferation of new vessels on the iris and in the angle. Retinal hypoxia due to various causes is the major factor responsible for the development of this condition.

The commonest etiological factor in this study was PDR (45.23%) followed by CRVO (33.33%). Other causes included CRAO, combined occlusion, CAOD, retinal vasculitis, chronic uveitis and Coats' disease. The cause of NVG could not be determined in one patient.

References :

1. Tripathi R C et al: Increased levels of VEGF in aqueous humor of patients with neovascular glaucoma. *Ophthalmology* 1998; 105 : 232
2. Tolentino MJ et al : VEGF is sufficient to cause iris neovascularization and neovascular glaucoma in a non human primate, *Arch Ophthalmol* 1996 114:964
3. Brown CC, Magargal LE, Schachat A et al: Neovascular glaucoma etiological considerations. *Ophthalmology*. 1984 91: 315
4. Konareva – Kostianeva M : Neovascular glaucoma. *Folia Med (Plovdiv)*. 2005; 47(2): 5 – 11

IJSER